



## **Dossier 16**

**M. EL HAJJAM**

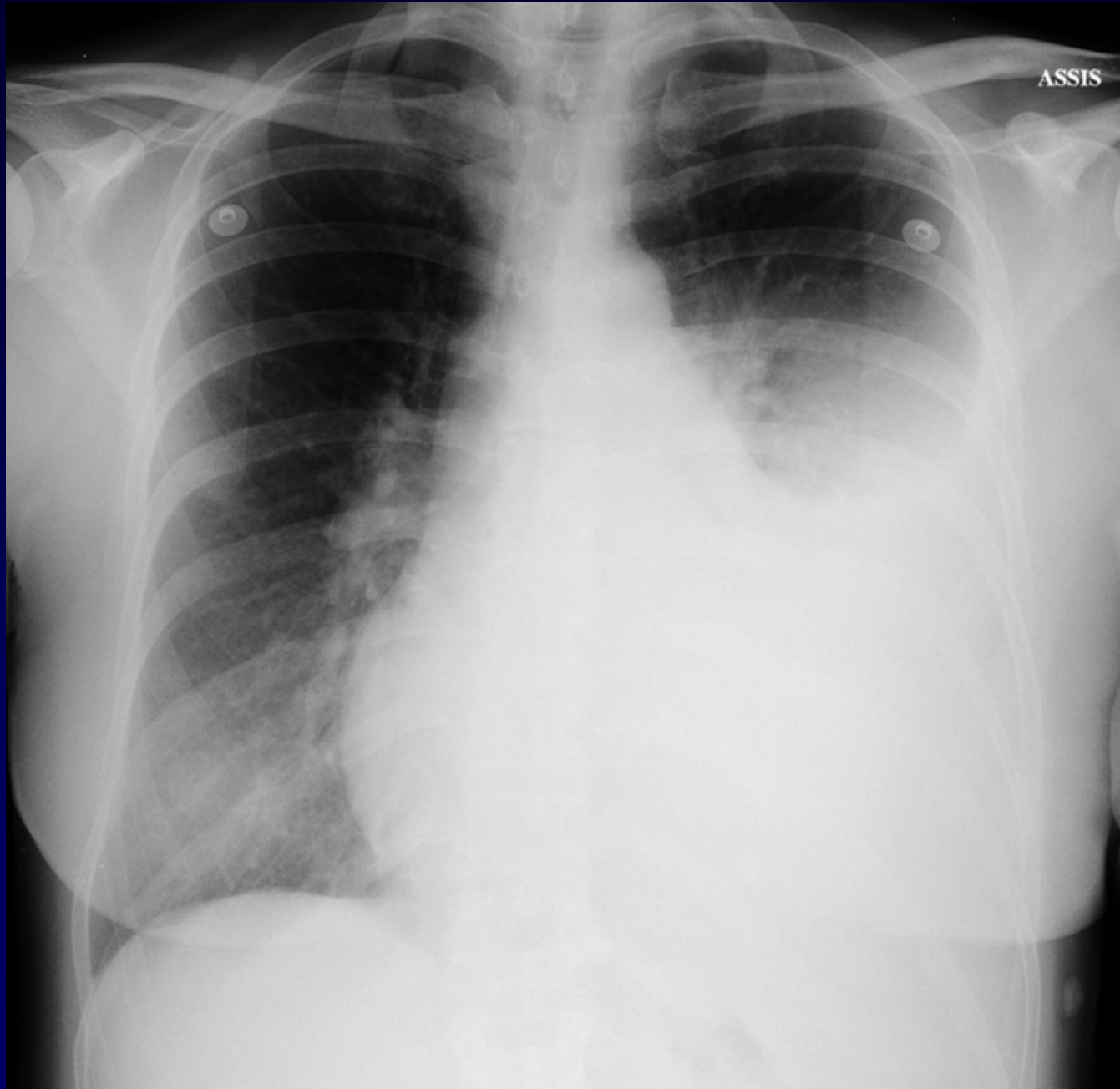
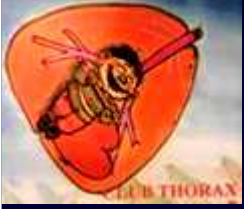**P. LACOMBE**

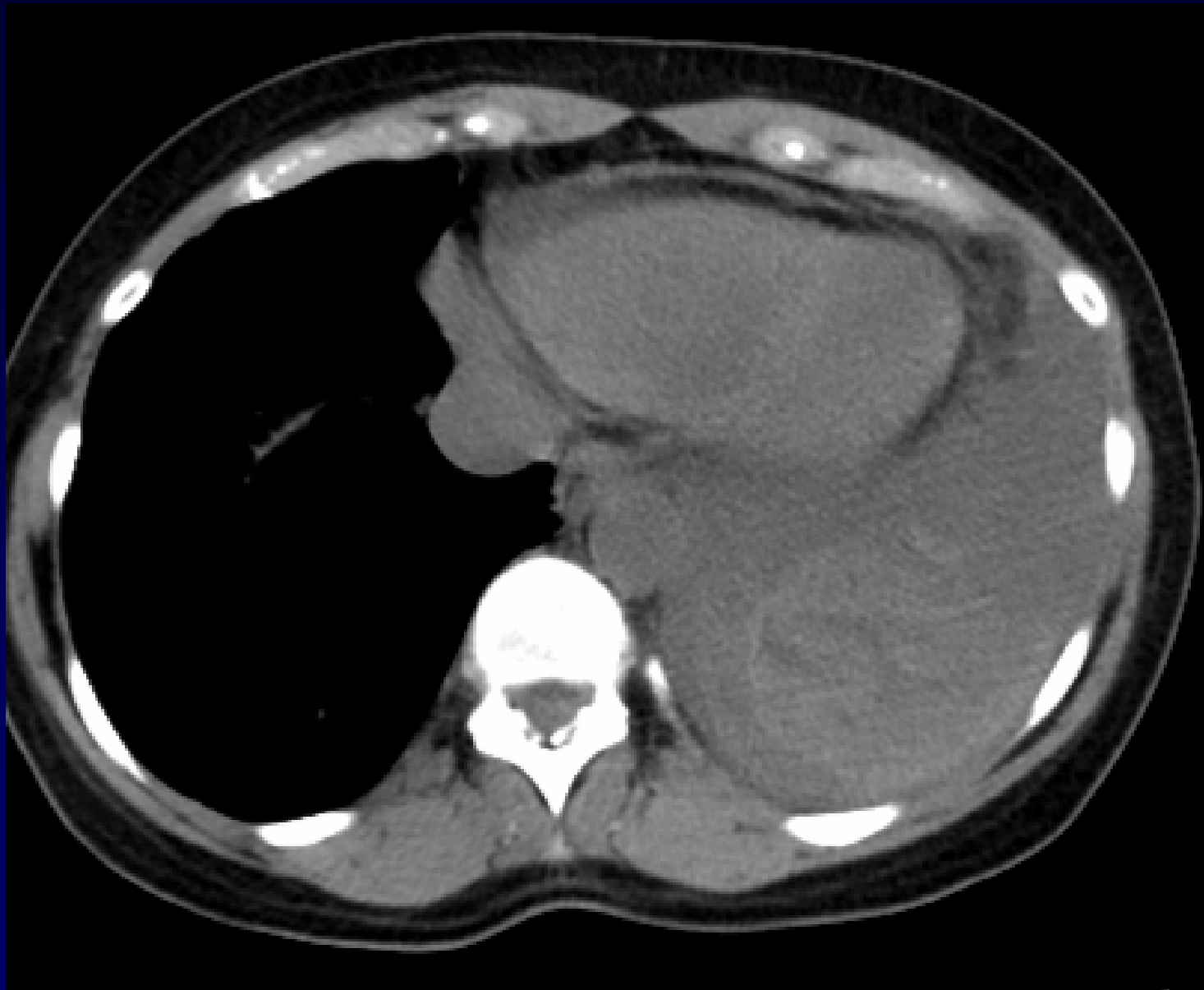
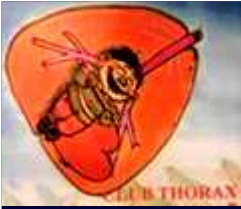**Femme de 56 ans.**

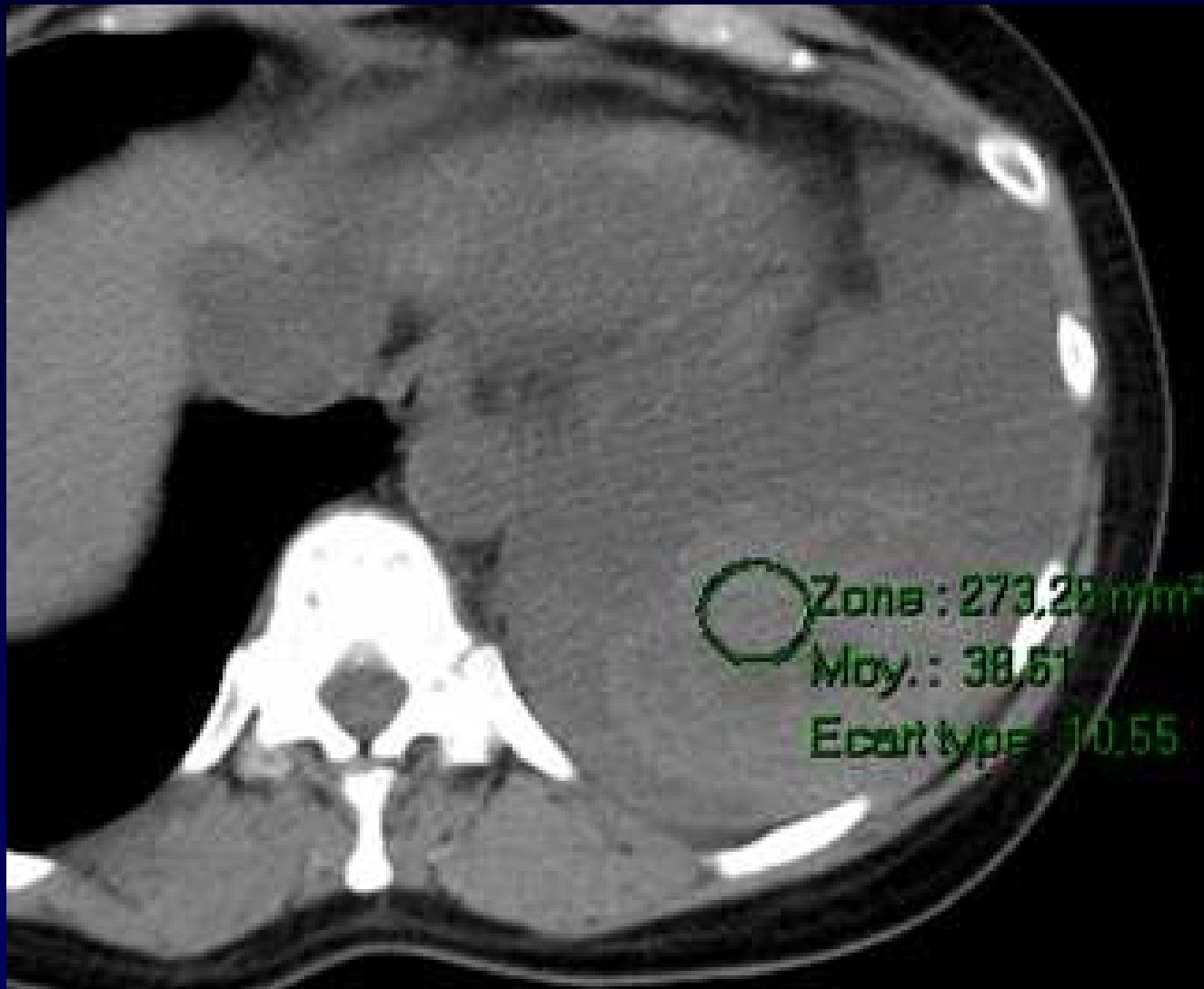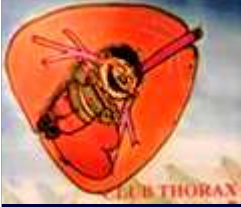**Colombienne, en vacances à Paris**

**Douleur thoracique gauche**

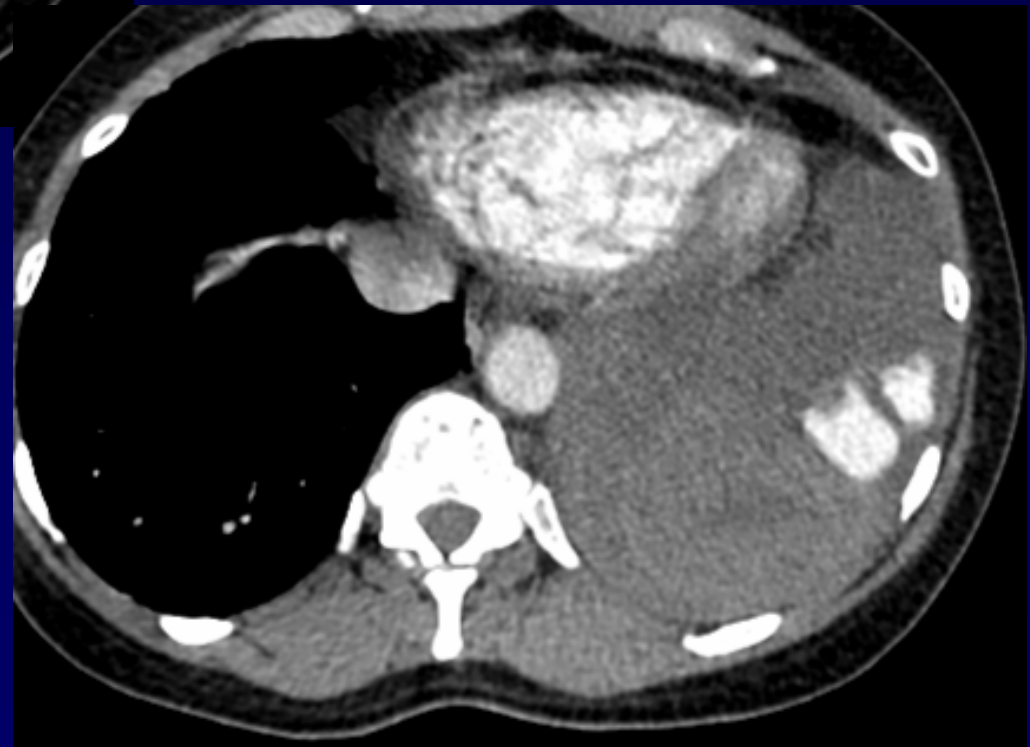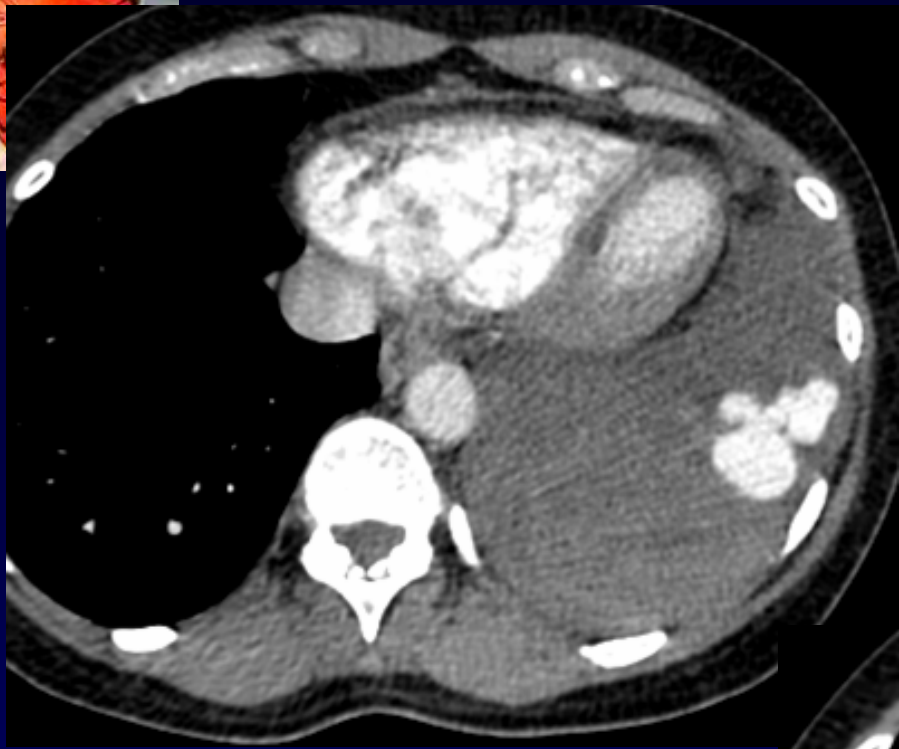**Dyspnée**

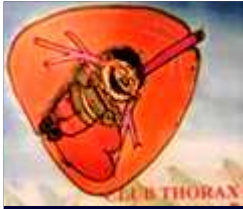




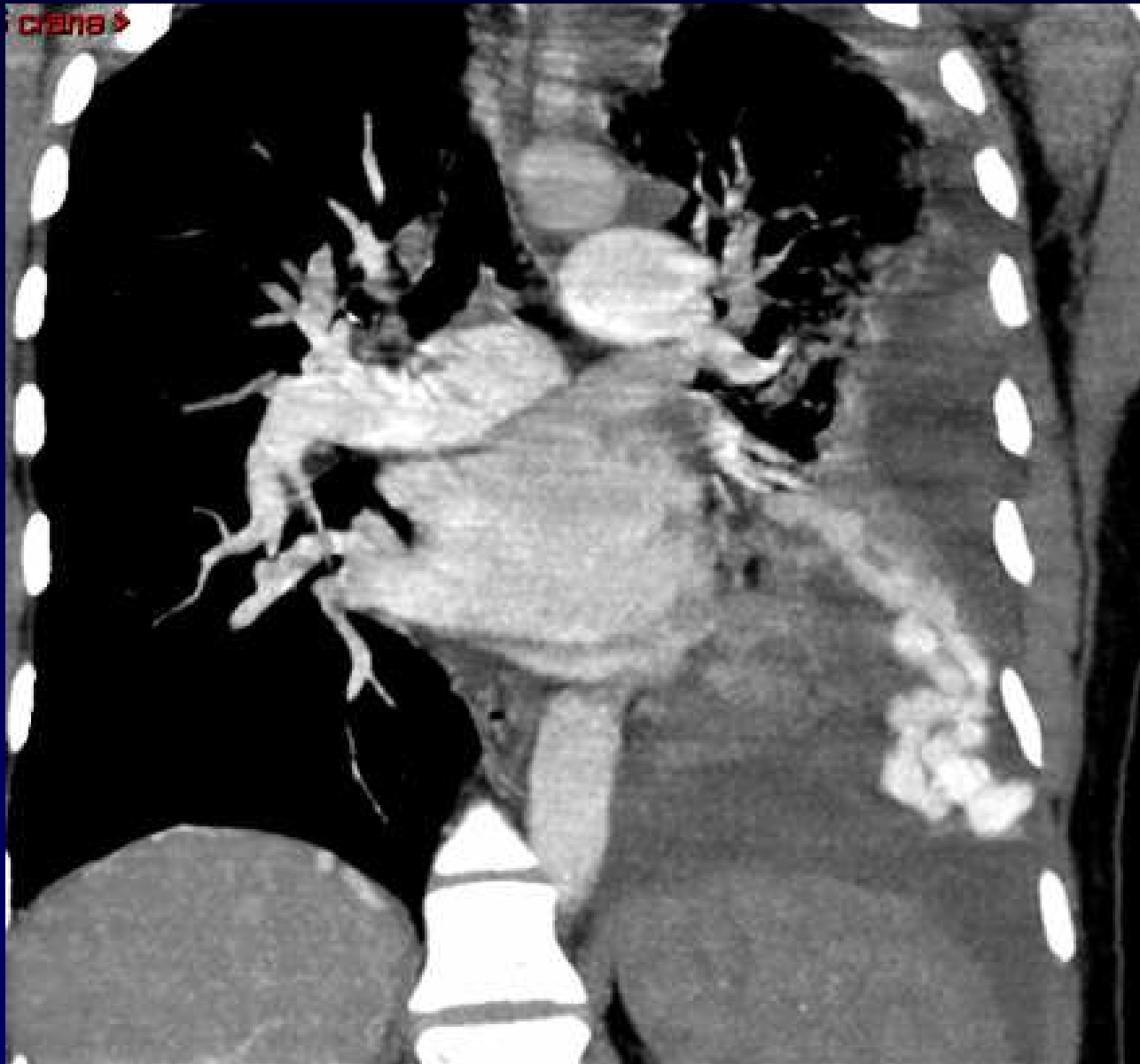
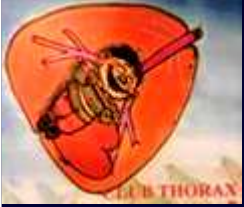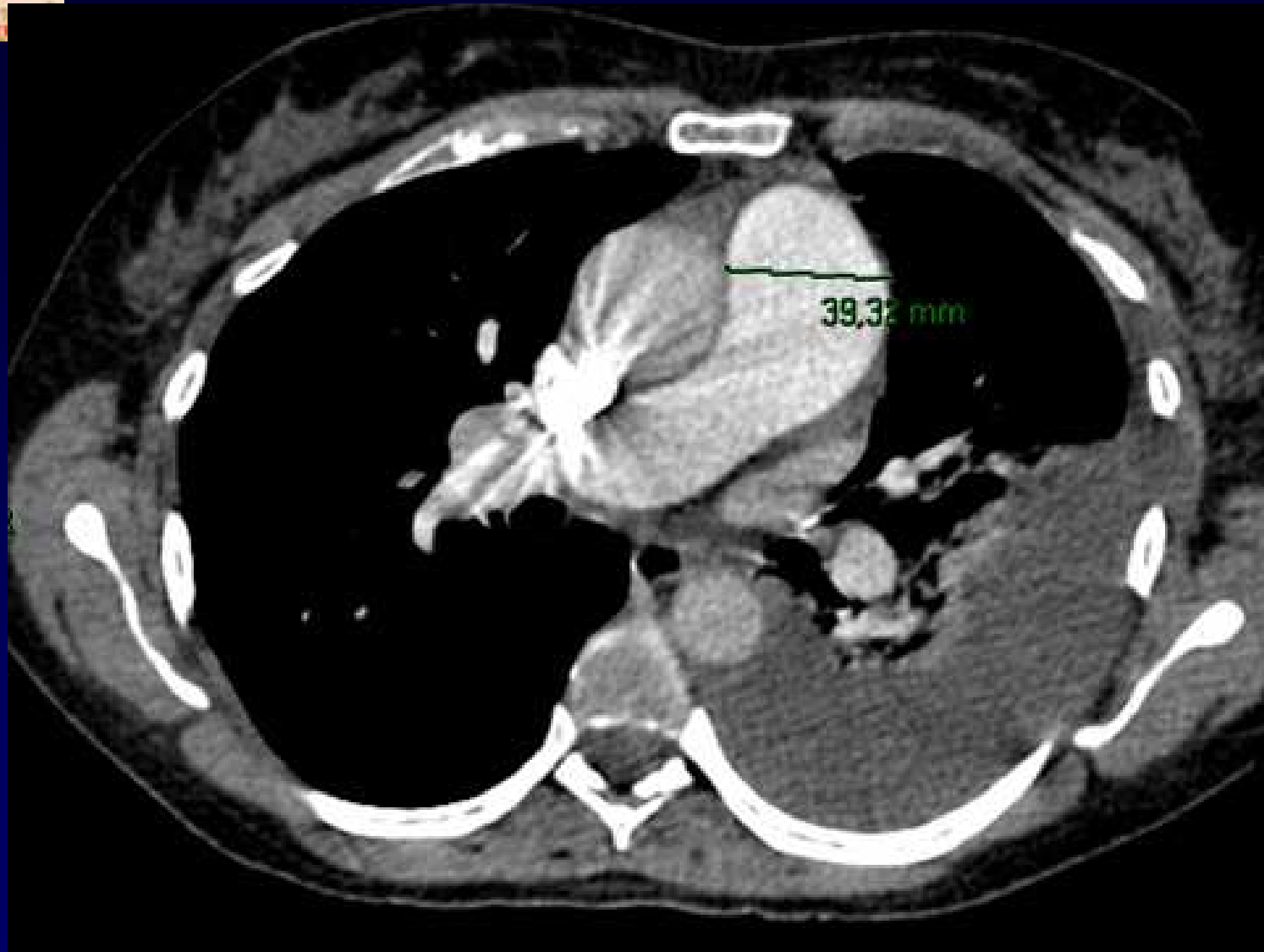
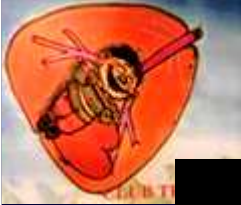**Hémothorax gauche + hématome**





**Diagnostic ?**



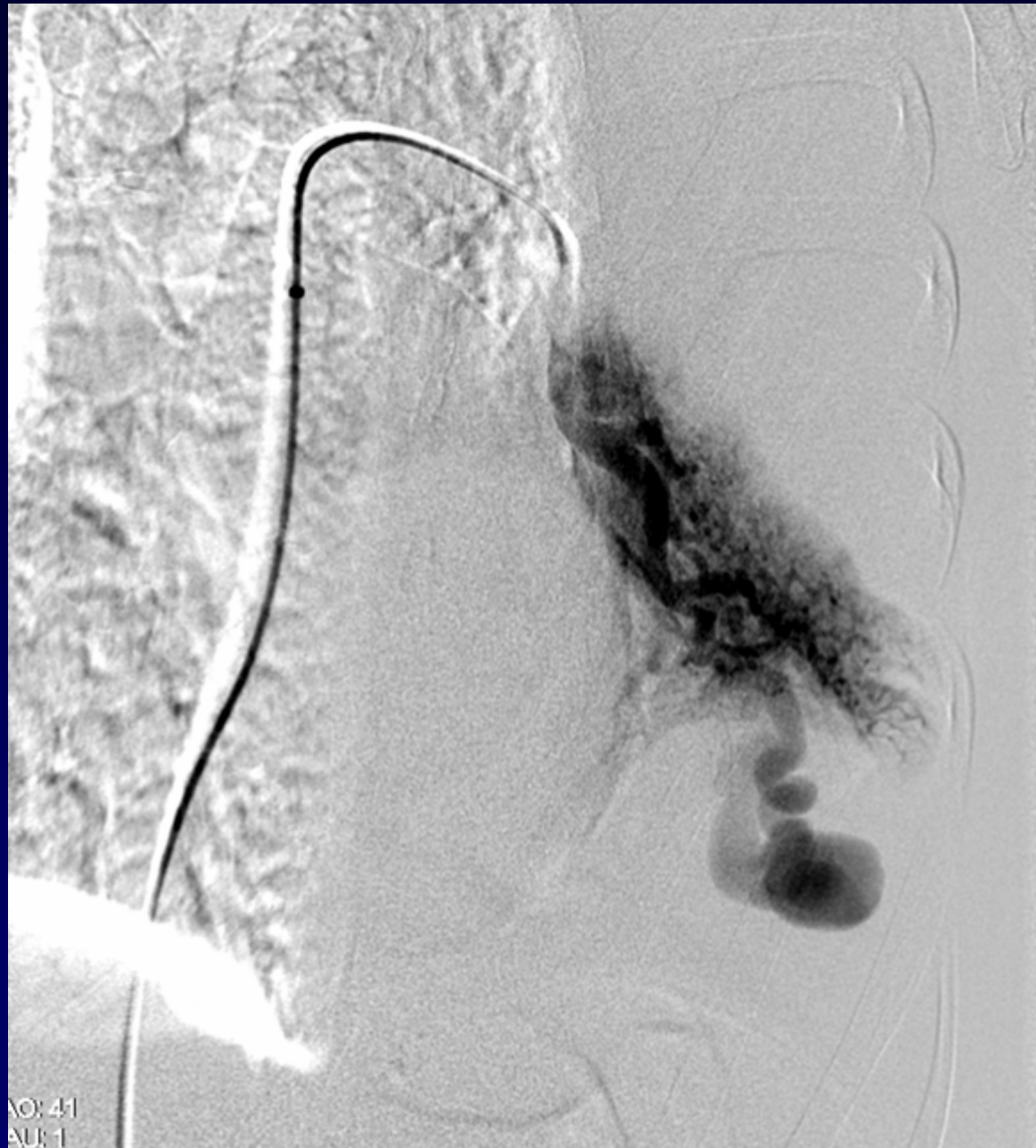


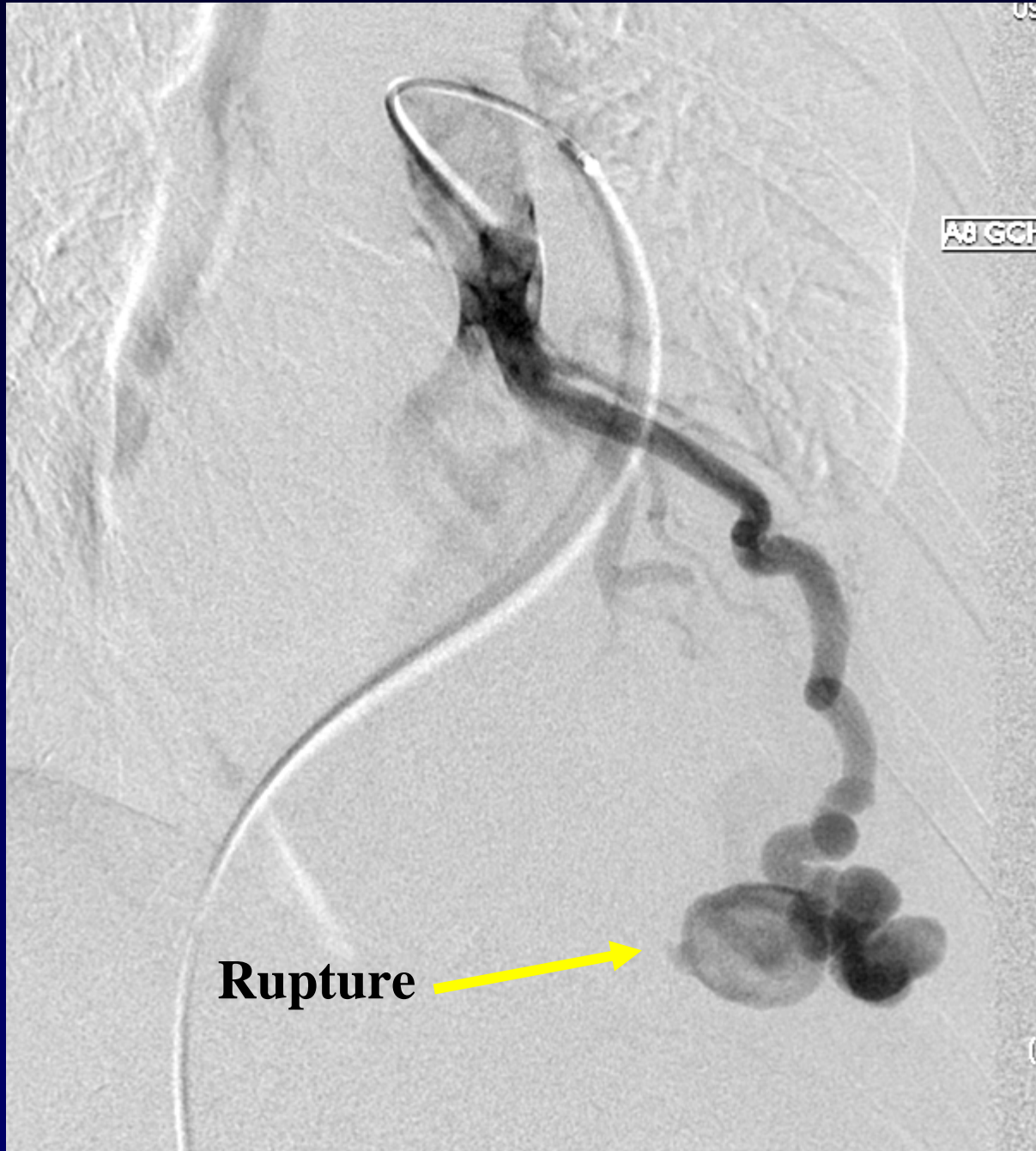


## **Diagnostic**

**Rupture intra-pleurale gauche d'une fistule artério-veineuse pulmonaire (MAVP) rentrant dans le cadre de la maladie de Rendu Osler**

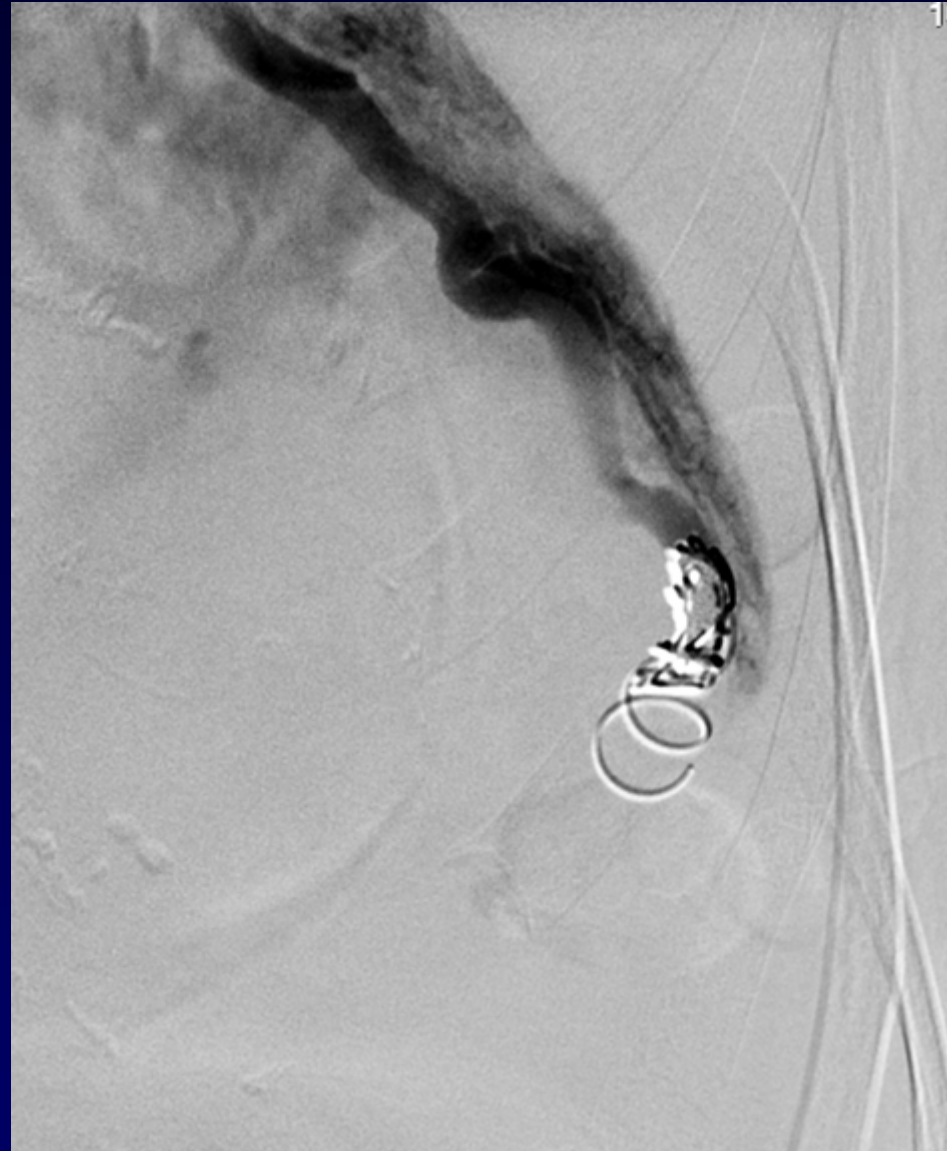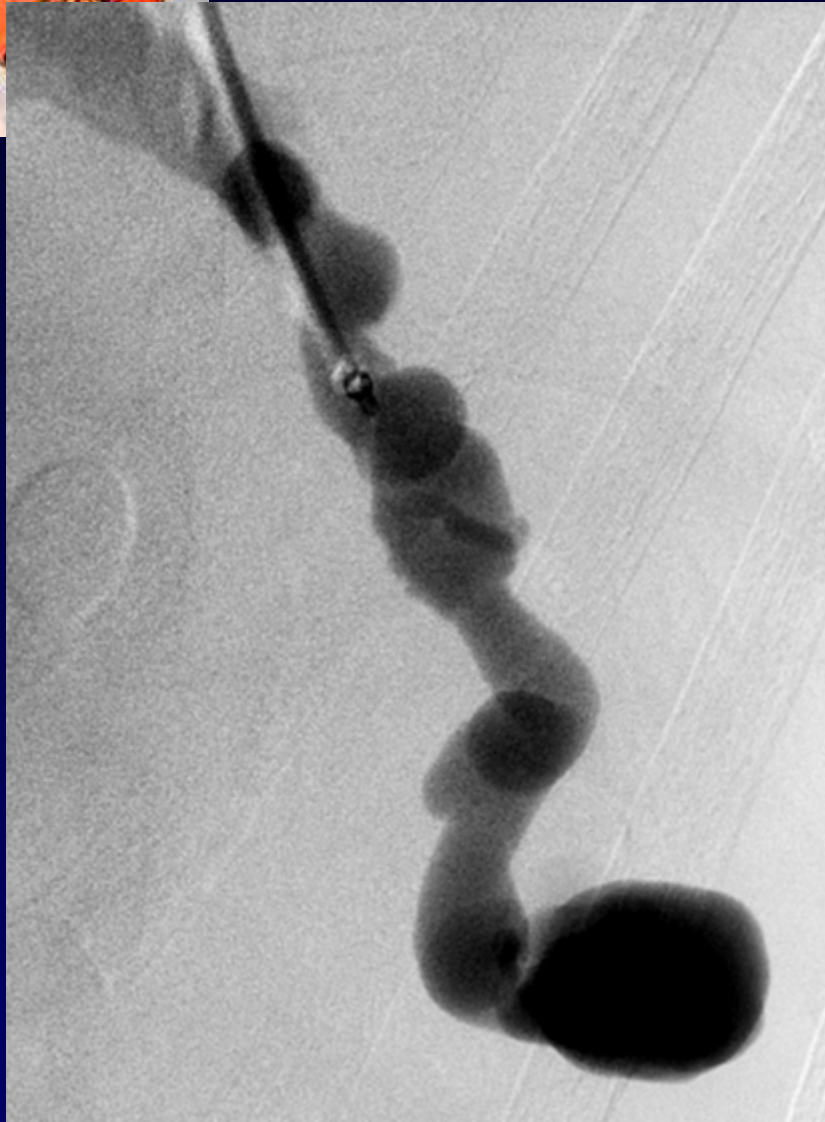
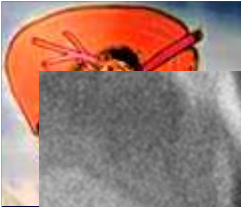
**Codage : Poumon – Cardiovasculaire - Congénital**





**Rupture**





**Vaso-occlusion par spirales métalliques**



## Référence

**P. Lacombe et al.**

**Malformations artério-veineuses pulmonaires :  
Diagnostic et traitement.**

*Sang Thrombose Vaisseaux 2008 ; 20 (1) : 34-42.*